

Original article:

Location of the mental & mandibular foraminae to give nerve block

¹Dr.Rakesh Ranjan , ²Dr Mahesh Taru , ³Dr Sathya Lakshmi

¹Department of Anatomy, Nalanda Medical college, Patna, Bihar, India

²Department of Anatomy, Malabar Medical College and research Center, Calicut, Kerala, India

³Shri Sathya sai Medical College, Chennai, India

Corresponding author: Dr.Rakesh Ranjan

ABSTRACT:

INTRODUCTION: Mental nerve is a branch of inferior alveolar nerve which is from the mandibular division of the Trigeminal nerve. The inferior alveolar vessels & nerve pass through the mandibular foramen and divides into mental & incisive branch to supply the lower jaw, exit at the mental foramen as the mental vessels & nerve..

MATERIALS & METHODOLOGY: In the present study 120 mandibles were used . The following distances were measured with the help of Vernier caliper . The position of the mandibular foramen in relation to the borders of the ramus of the mandible with the help of Vernier caliper. 2. The position of the mental foramen in relation to the alveolar margin and lower border of the mandible. 3. The mental foramen distance from the mid line.

OBSERVATIONS: In the present study the mean of the mental foramen to alveolar border on the right side and the left side were same(1.4cm). The mean distance from the mental foramen to the lower border of mandible is same on right and left side (1.32cm). The mean distance from the mental foramen to the midline of the body of mandible is same on right and left side (2.5cm).

CONCLUSION: Details about mandibular foramen will be helpful to reduce failures in inferior alveolar nerve block. The correct localization of the mandibular foramen will assist in performing proper and safe split osteotomy procedures on the mandible.

INTRODUCTION:

Mental nerve is a branch of inferior alveolar nerve which is from the mandibular division of the Trigeminal nerve. The inferior alveolar vessels & nerve pass through the mandibular foramen and divides into mental & incisive branch to supply the lower jaw, exit at the mental foramen as the mental vessels & nerve.. Exact position of mandibular & mental foramen is very important to block these nerves by local infiltration. The aim of this study is to locate the mental foramen in relation to body and mandibular foramen foramen in relation to the ramus

of the mandible in different age groups and in different sex to give nerve block .

MATERIALS & METHODOLOGY:

In the present study 120 mandibles were used . The following distances were measured with the help of Vernier caliper .

The position of the mandibular foramen in relation to the borders of the ramus of the mandible with the help of Vernier caliper. 2. The position of the mental foramen in relation to the alveolar margin and lower border of the mandible. 3. The mental foramen distance from the mid line.

The bones were collected from department store as well as from students set. The sample were collected on the basis of random sampling.

OBSERVATIONS:

In the present study the mean of the mental foramen to alveolar border on the right side and the left side were same(1.4cm). The mean distance from the mental foramen to the lower border of mandible is same on right and left side (1.32cm). The mean distance from the mental foramen to the midline of the body of mandible is same on right and left side (2.5cm). The mean distance from the mandibular foramen to anterior border of the ramus mandible was same (1.6cm). The mean distance from mandibular foramen to posterior border of the mandible on the right and left side were same (1.4cm). The mean distance from mandibular foramen to mandibular notch were 2.27cm & 2.25cm on the right and left side respectively. The mean distance from mandibular foramen to lower border of mandible were 2.42cm and 2.25cm on the right and left side respectively.

DISCUSSION:

The **mandibular foramen** is an opening on the internal surface of the ramus of the mandible for divisions of the mandibular nerve and blood vessels to pass through.

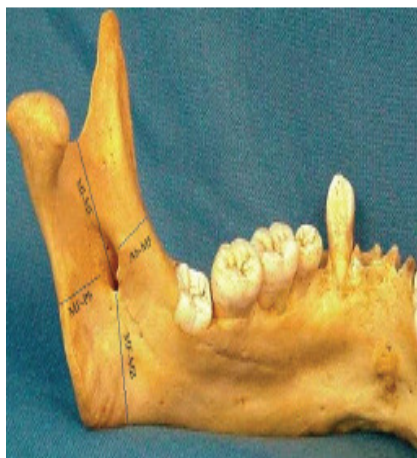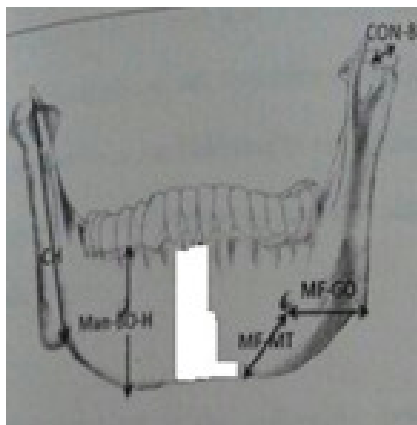
The mandibular nerve is one of three branches of the trigeminal nerve, and the only one having motor innervation. One branch of it, the inferior alveolar nerve as well as the inferior alveolar artery enter the foramen traveling through the body in the mandibular

canal and exit at the mental foramen on the anterior mandible at which point the nerve is known as the mental nerve. These nerves provide sensory innervation to the lower teeth, as well as the lower lip and some skin on the lower face. The knowledge of the position of the MF is of a great importance for many procedures in dentistry. Its precise location enables a more effective anesthesia, which in turn leads to an easier patient conditioning. The importance of knowledge of the position of MF in the inferior alveolar nerve block was mentioned in several studies which were mentioned in the introduction part of this text. The knowledge of distance of MF from the posterior border of ramus and the inferior border of mandible and condyle would be helpful in the innovation of new extra oral inferior alveolar nerve block techniques. It is also helpful to study of dental X-rays.

Although it is being mentioned in the literature, the anatomical variation is the cause for failure of anesthesia but this study found the foramen was always at the level of the occlusal plane or below the occlusal plane. Therefore, deposition of anesthetic solution above the foramen level should anesthetize the nerve.

CONCLUSION:

Details about mandibular foramen will be helpful to reduce failures in inferior alveolar nerve block. The correct localization of the mandibular foramen will assist in performing proper and safe split osteotomy procedures on the mandible.



REFERENCES:

1. Ashkenazi M, Taubman L, Gavish A. Age-associated changes of the mandibular foramen position in anteroposterior dimension and of the mandibular angle in dry human mandibles. *Anat Rec.* 2011; 294:1319–25.
2. Bavitz J B, Harn S D, Hansen C A, Lang M. An anatomical study of mental neurovascular bundle – implant relationships. *Int. J Oral Maxillofac Implants;* 1993; 8 (5) 563-567.
3. Soikkonen K, Wolf J, Ainamo A, Xie Q. Changes in the position of the mental foramen as a result of alveolar atrophy. *J Oral Rehabil,* 1995 Nov., 22 (11): 831-833.
4. Singh S K, Gopinathan K, Dhalla U, Chhabra S. Variation in the position and number of mental foramen in mandibles of North Indian Population. *J. Anat. Soc. India,* 1992; 41 (1): 47-51.
5. Warwick R. The relation of direction of the mental foramen to the growth of the human mandibles. *J. Anat.,* 1950; 84: 116-120.
6. Gupta S, Jagdish SS. Study of anatomical variations and incidence of mental foramen and accessory mental foramen in dry human mandibles. *NJMR* 2012;2:28-30.